

Partial Carpal Arthrodesis Plate



User Guide



ParCA User Guide

Introduction

Third degree sprain of the palmar carpal fibrocartilage in the dog results in pain, lameness, subluxation and osteoarthritis as an inevitable sequelae to injury (Farrow, 1977). Hyperextension or valgus loading due to jumping or falling may induce palmar carpal instability (Willer et al. 1990). Pancarpal arthrodesis (PCA) has been advocated for the treatment of palmar ligament insufficiency (Parker et al. 1981). However, if ligament injury involves only the middle carpal and / or carpometacarpal joint, then partial carpal arthrodesis (ParCA) has been shown to re-establish palmar stability and limb function (Newton, 1985). ParCA carries the biomechanical advantage over PCA of maintained antebrachio-carpal motion during gait (Haburjak et al. 2003). Techniques described for ParCA include use of a 'T' plate (Smith et al. 1991), cross pinning (Haburjak et al. 2003) intramedullary pinning or by external coaptation alone (Slocum et al. 1982, Gambardella et al. 1982). Regardless of technique, external coaptation is recommended for between four and eight weeks subsequent to surgery to avoid implant failure. Unfortunately the need for prolonged coaptation is frequently associated with significant complications (Oakley, 1999, Anderson et al, 2000).


Until now, plate fixation techniques for ParCA have utilised 'T' plates, employing two screws placed in the radial carpal bone and attachment to a single metacarpal bone (III). There are technical limitations to the use of conventional T plates for ParCA that may be associated with poor functional outcomes or persistent lameness. The carpus hyperextends during stance passed the 10 – 15° of normal carpal extension in the standing dog. This means that traditional 'T plates' applied to the radial carpal bone may impinge on the radial styloid process and cranio-distal radius during stance which may cause plate loosening, bone damage and exacerbate osteoarthritis, effusion & lameness. Attempts to place traditional T plates more distally on the radial carpal bone to avoid impingement, result in poorer radial carpal bone purchase and thus increased risk of fracture, screw loosening and ultimately failure of arthrodesis.

Design Features

The ParCA plate is machined from surgical grade 316LVM stainless steel; batch marked and manufactured to internationally recognised ASTM standards. Each batch of raw material undergoes an intercrystalline corrosion test in accordance with ASTM A262. There are seven sizes of

ParCA plates in the range and these can be identified on the template at the rear of the user guide (also available on-line at www.orthomed.co.uk

The Orthomed ParCA implants are the first range of plates designed specifically for canine partial carpal arthrodesis. The plate has several custom design features which make its use ideal for this surgery.



The top of the plate is bevelled by 60 degrees and laterally recessed to avoid impingement on the cranio-distal aspect or styloid process of the radius. The proximal plate holes are angled at 60 degrees proximally allowing more distal placement of the plate on both the radial and ulnar carpal bone than a conventional plate, whilst still engaging the body of these bones effectively for optimal screw purchase. Both of these design features avoid impingement by the radial styloid process and the disto-cranial radius on the plate during locomotion.

Proximally there are three holes in the plate. A central hybrid hole (hole two) accepting a neutral cortical 2.0, 2.4 or 2.7mm screw in smaller plate sizes, a 2.4 or 2.7mm in larger plate sizes and either a 2.7 or 3.5mm screw for giant breeds (see template at rear of brochure for screw hole sizes for each plate). Holes one & three are oval compression holes allowing placement of both a second screw in 'buttress' in the radial carpal bone and a third screw in the ulnar carpal bone placed in compression towards the radial carpal bone. Holes one and three accept 2.0mm screws in smaller plate sizes and 2.7mm screws in larger plate sizes. Compression and stability across the radio-ulnar carpal bone joint encourage primary bone healing in an effort to promote minimal callus formation between these bones within the preserved antebrachio-carpal joint. Due to the facility to apply the screws in holes one and three in

compression in the ulnar or buttress in the radius, one plate design can be applied to either the left or right carpus. Proximal plate holes increase incrementally 1 millimetre in distance from each other as plate sizes increase. There is a single 0.8mm hole perforating the plate immediately below the central round hole (hole two) to allow a small K wire or hypodermic needle to be placed through the plate and into the space immediately distal to the radial carpal bone to define the optimum proximo-distal position of the plate and maintain accurate proximo-distal alignment of the plate during placement.

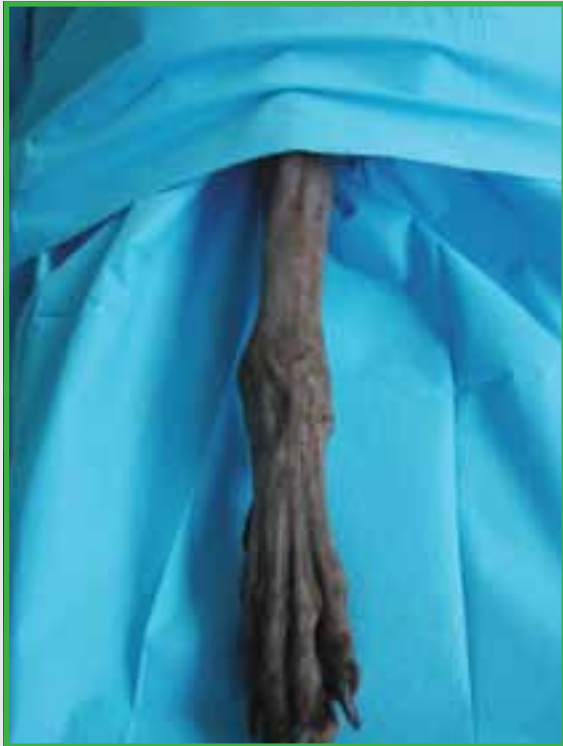Distally there are three pairs of screw holes (holes four to nine). These holes accept 2.0mm screws in smaller plate sizes and 2.7mm screws in larger plate sizes (See template at rear of brochure for plate/screw options). The proximal pair of holes are placed close to midline and angled at 10°; the middle pair is slightly more offset and angled at 20° and the most distal pair of holes is significantly offset from the midline and angled at 30°. This arrangement optimises the screw-bone contact and accommodates the anatomical divergence between metacarpals three and four distally. The biomechanically sympathetic fixation of the implant along most of the length of two metacarpals also minimises the risk of metacarpal fracture. The underside of the plate is smoothly contoured without steps which would act as stress risers. Proximally, a curved under-surface conforms to the carpal bones. Distally the surface features a “keel” to accommodate the dorsal aspects of metacarpals three and four. Two additional 0.8mm hypodermic needle holes perforate the distal length of the plate to align the long axis of the plate directly between metacarpals 3 and 4 prior to placing screws. The metacarpal part of the implant increases in length with increased size to provide optimum coverage of the metacarpal bones, (approximately 80% of the metacarpal is advised). The distal aspect of the plate is tapered to facilitate tension free skin closure and to reduce stress risers at the base of the plate.

References

- Anderson, DM, White, RAS. (2000) Ischaemic bandage injuries: A case series and review of the literature. *Veterinary Surgery* 29: 488 – 498
- Clarke SP, Ferguson JF, Miller A (2008). Clinical evaluation of pancarpal arthrodesis using a castles plate in 11 dogs. *Veterinary Surgery* 2009, 38:852 - 860
- Farrow, CS. (1977) Carpal sprain injury in the dog. *Journal of the American Veterinary Radiology Society*. 18: 38 - 44
- Gambardella PC, Griffiths RC. (1982) Treatment of hyperextension injuries of the canine carpus. *Compendium of Continuing Education for the Practicing Veterinarian* 4: 127 – 131
- Haburjak JJ, Lenehan TM, Davidson CD, Tarvin GB, Carlson KR, Hayes A. (2003) Treatment of carpometacarpal and middle carpal joint hyperextension injuries with partial carpal arthrodesis using a cross pin technique: 21 cases. *Veterinary and Comparative Orthopaedics and Traumatology* 16: 105 - 111
- Newton CD. Arthrodesis of the shoulder, elbow and carpus. In: Newton, Nunamaker DM, eds. *Textbook of small animal orthopaedics*. Philadelphia: JB Lippencott Co, 1985; 565-570
- Oakley, RE (1999) External coaptation. *Veterinary Clinics of North America*. 29 (5) 1083 – 1098
- Parker RB, Brown SG, Wind AP. Pancarpal arthrodesis in the dog: a review of 45 cases. *Veterinary Surgery* 1981; 10: 35 -43
- Slocum B, Devine, T. (1982). Partial carpal arthrodesis in the dog. *Journal of the American Veterinary Medical Association*; 180: 1204 – 1208
- Smith MM, Spagnola J. (1991) T-plate for middle carpal and carpometacarpal arthrodesis in a dog. *Journal of the American Veterinary Medical Association*. 199: 230 – 232
- Willer, R.L, Johnson, K.A, Turner, T.M, Piermattei, D.L. (1990) Partial carpal arthrodesis for third degree carpal sprain: A review of 45 Carpi. *Veterinary Surgery*, 19(5) 334-340

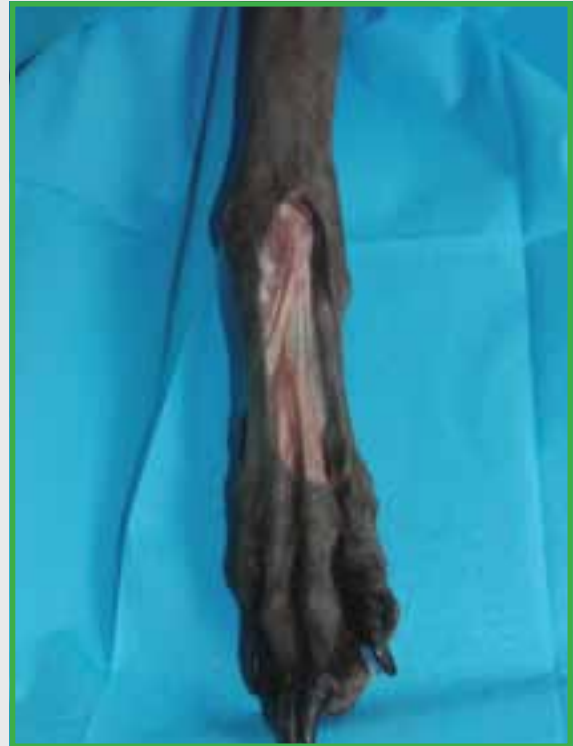ParCA User Guide

Surgical Technique



01

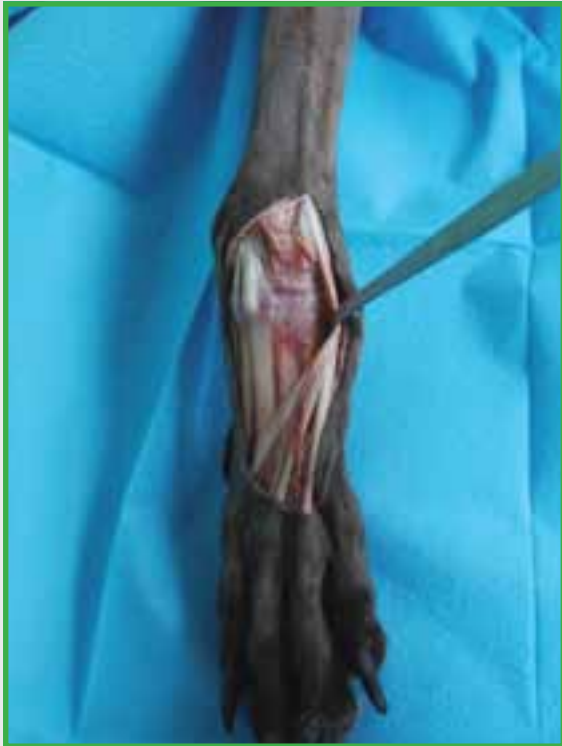With the patient in dorsal recumbancy the limb is clipped from dorsal midline to the digits and draped such that the elbow to the digits is exposed.



02

A paramedian curvilinear skin incision is made from one centimetre proximal to the antebrachio-carpal joint, extending distally to stop just short of the metacarpophalangeal joints.

Care is taken to avoid cutting the cephalic vein branches, extensor retinaculum or digital extensor tendons distally.

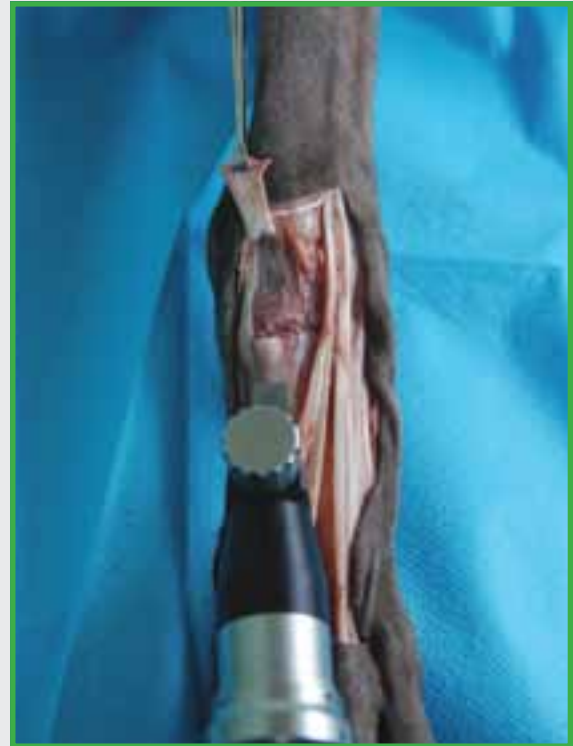

03

The digital extensor tendons are identified on the dorso-lateral aspect of the manus.

The tendon of the abductor pollicis longus is mobilised and retracted proximo-medially.

The remaining extensor tendons are retracted laterally out of the surgical field.



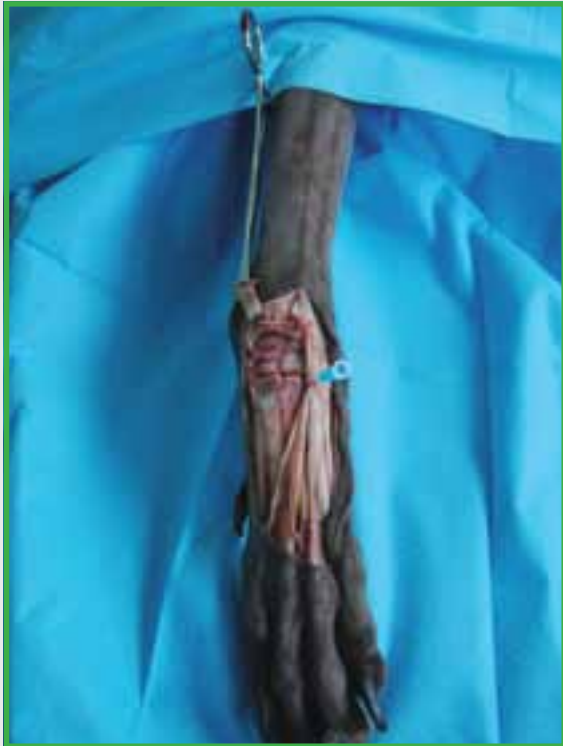04

The two insertions of the tendon of the extensor carpi radialis muscle are identified at their respective insertion on the 2nd and 3rd metacarpal heads.

The insertion of the extensor carpi radialis on the 3rd metacarpal bone only is sectioned at its insertion and reflected proximally.

A sagittal saw or spinal burr is used to flatten the heads of the 3rd (and 4th) metacarpal bones to ensure the keel of the plate is positioned flat on the length of the metacarpal bones.

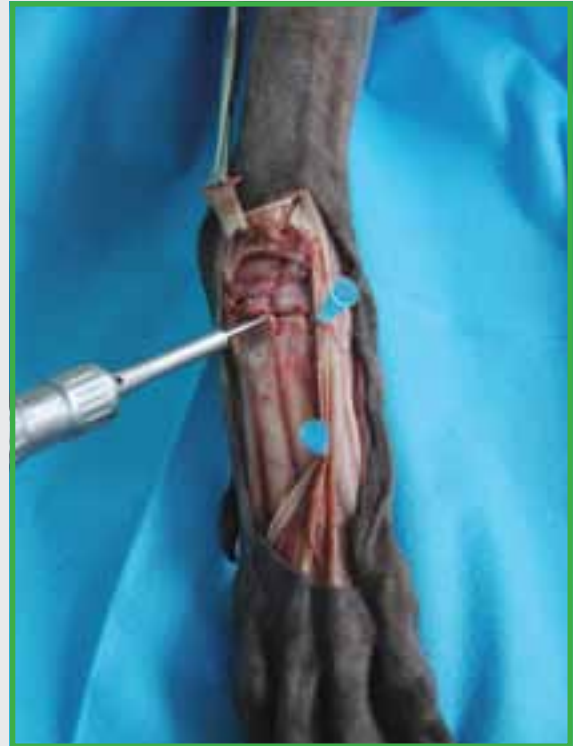ParCA User Guide



05

The joint capsule and dorsal ligament of the intercarpal and carpo-metacarpal are identified and excised with a sharp scalpel or monopolar diathermy.

Care is taken to avoid injury to the retracted extensor tendons, vascular structures and collateral ligaments which should be retracted with hypodermic needles or Hohmann retractors.

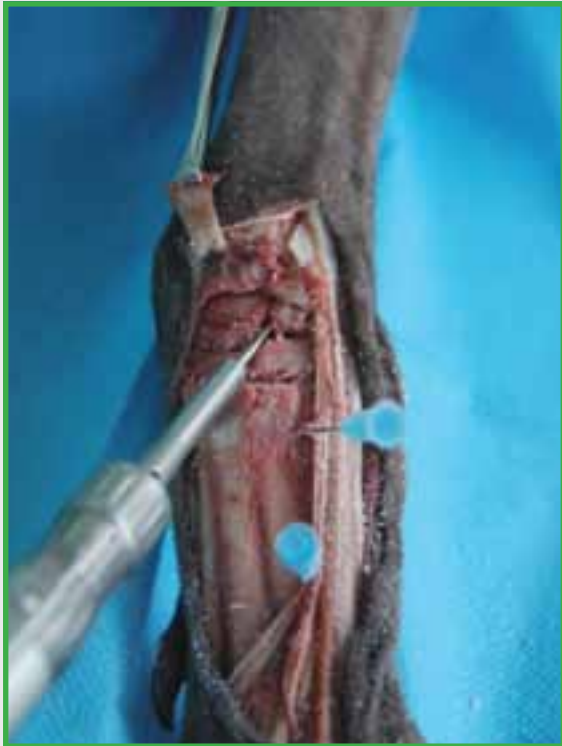

06

The dissection is complete – the middle carpal and carpal-metacarpal joints are easily accessed with flexion of the carpus and judicious use of the Hohmann retractor.

Articular cartilage is debrided from the carpal-metacarpal and inter-carpal joints with a spinal burr.

Once all articular cartilage has been removed, numerous small diameter holes are drilled 1mm-2mm deep into each joint surface to give a honey-comb network of vascular channels.



07

Cartilage is then carefully debrided from the radio-ulnar carpal joint via their distal surface in an effort to spare as much subchondral bone as possible with minimal disruption to the articular contour of the antebrachiocarpal joint.

Bone graft is then placed in the middle carpal and carpo-metacarpal joints. Retraction of the extensor tendons can be achieved with hypodermic needles.



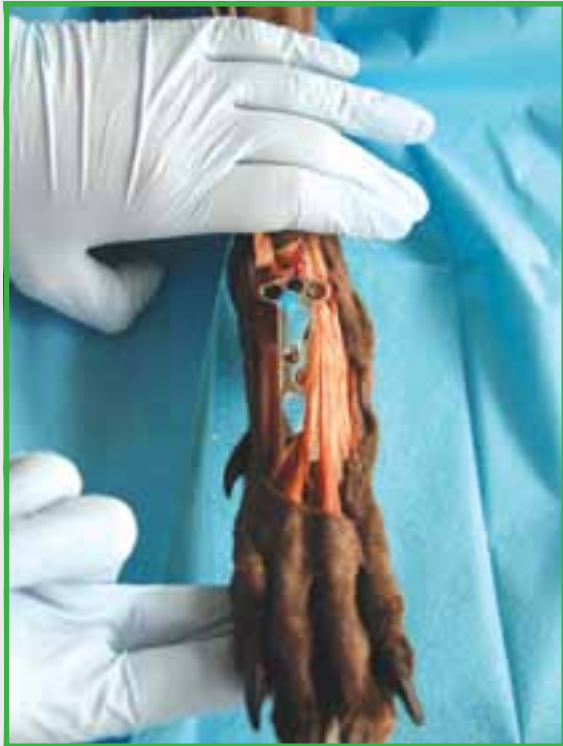08

The appropriate size ParCA plate is placed on the bone. The proximal aspect of the plate is aligned such that two holes aligns with the radial carpal bone and one hole aligns with the ulnar carpal bone.

The plate is then slid distally until a 21 gauge hyperdermic needle can be placed through the pin hole distal to the proximal central plate hole (hole 2) emerging immediately distal to the radial carpal bone, into the middle carpal joint.

The central alignment of the plate is maintained by then placing a further two 21 gauge needles through the small pin holes in the plate between metacarpals 3 & 4. The proximal needle bevel is then bent distally so as not to obscure the drill.

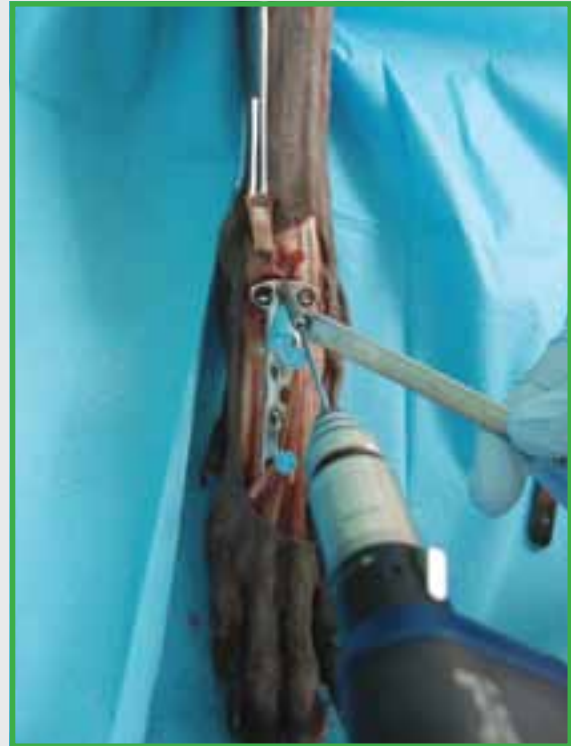ParCA User Guide



09

With the plate held in position with the three hypodermic needles the carpus is then maximally extended and potential impingement of the cranio-distal radius and radial styloid process assessed. If this is present the plate is relocated slightly more distally.

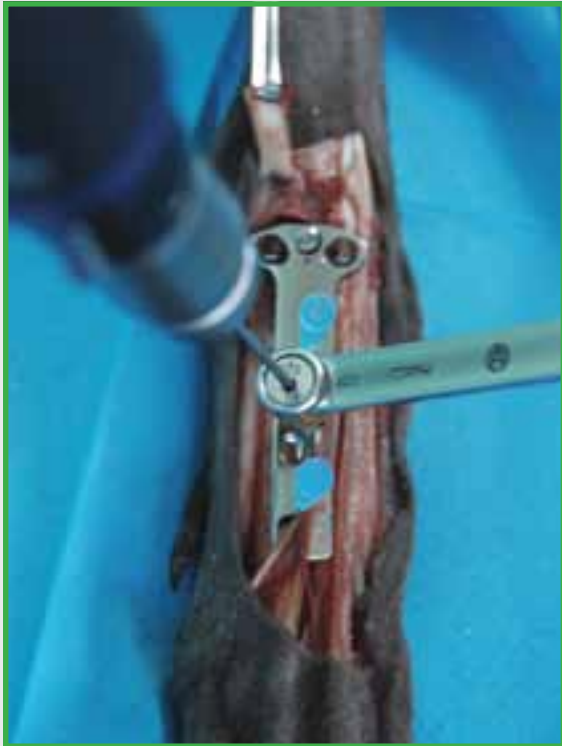IMPORTANT NOTE: *Screws for holes 1, 2 & 3 should be the same length as the measured hole. Do not add 2 – 4 mm as traditional for normal or self tapping screws. Placing screws longer than the measured depth results in impingement of the radial and ulnar carpal bone screw tips on the caudo-distal radius when the carpus is flexed, limiting flexion and predisposing to lameness and screw loosening.*



10

The carpus and ParCA plate are held in alignment while a 2.0mm hole is made through plate hole number 2 at a 60 degree angle proximally into the body of the radial carpal bone.

The hole is measured and a cortical screw placed that is the **same length** as the measured depth of the hole.

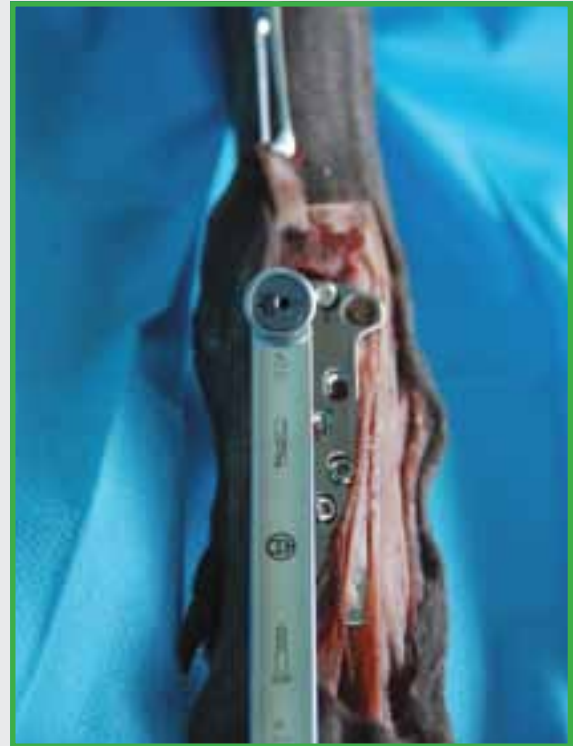

11

Holes 6 & 7 are oval load holes and these screws are placed next. A standard AO compression drill guide is used with a 2.0mm drill bit.

Note the distal screw holes are sequentially angled to provide better positioning of the screw within the metacarpal bone. It is important that both of the central screws are placed before either is tightened.

The hypodermic needles should be removed at this stage or they will become jammed once these screws are tightened.



12

Depending on whether the plate is being used on a left or right carpus, the second radial carpal screw is placed next (hole 1 if left carpus, hole 3 if right carpus). This screw is placed in buttress.

Using a standard AO compression guide, compression guide is reversed and the radial carpal bone drilled, again at a 60 degree proximal angle, parallel with screw 2.

The hole is measured and a cortical screw placed that is the **same length** as the measured depth of the hole.

ParCA User Guide

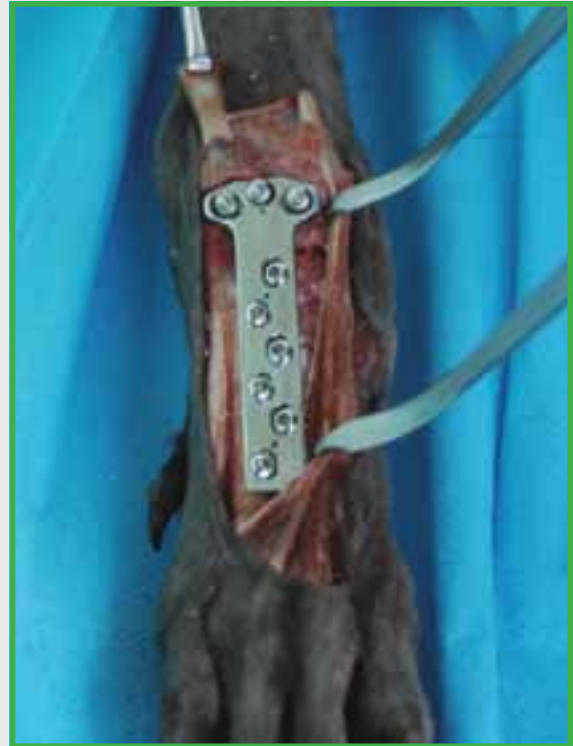

13

Depending on whether the plate is being used on a left or right carpus, the ulnar screw is placed next (hole 3 if left carpus, hole 1 if right carpus). This screw is placed in load using a standard AO compression guide.

The hole is drilled at a 60 degree proximal angle, parallel with the second radial carpal bone screw. The hole is measured and a cortical screw placed that is the **same length** as the measured depth of the hole.

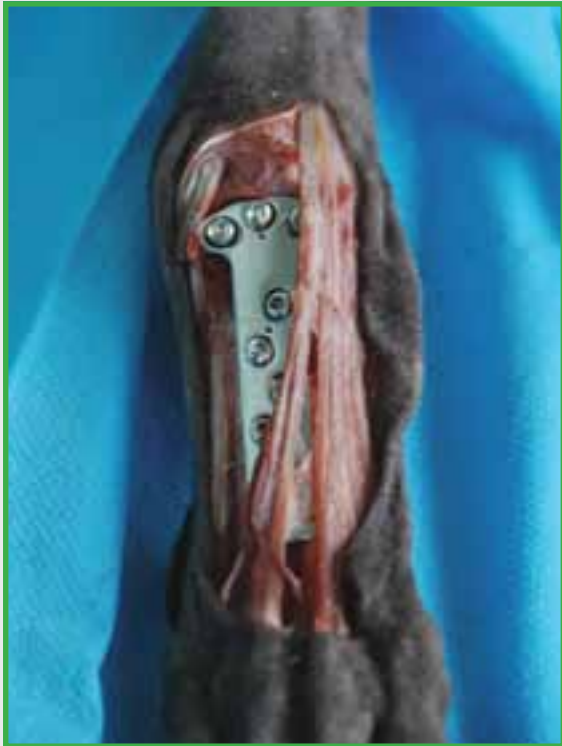The screw is placed and tightened and on tightening compresses the ulnar carpal bone against the radial carpal bone.



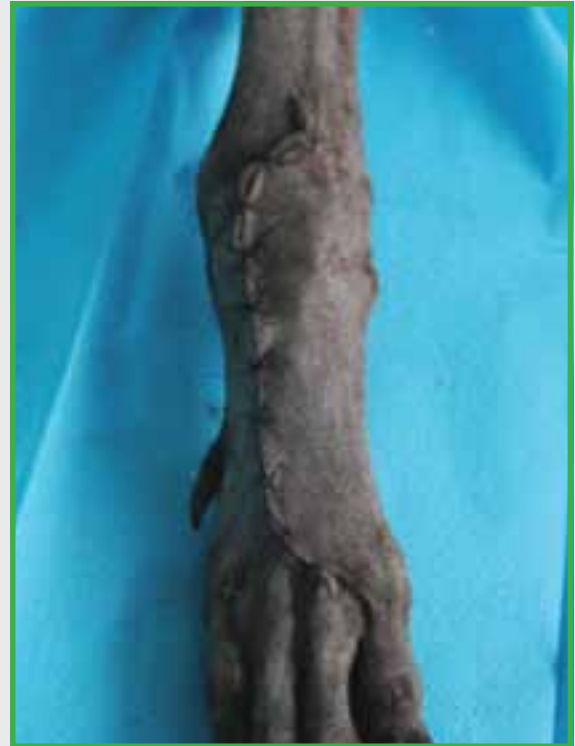14

The remaining two pairs of MC screws are placed using a neutral drill guide and a 2.0mm drill.

Take care to respect the angulations of these distal screw holes – the first pair of holes is angled off perpendicular at 10 degrees, the third pair at 30 degrees.

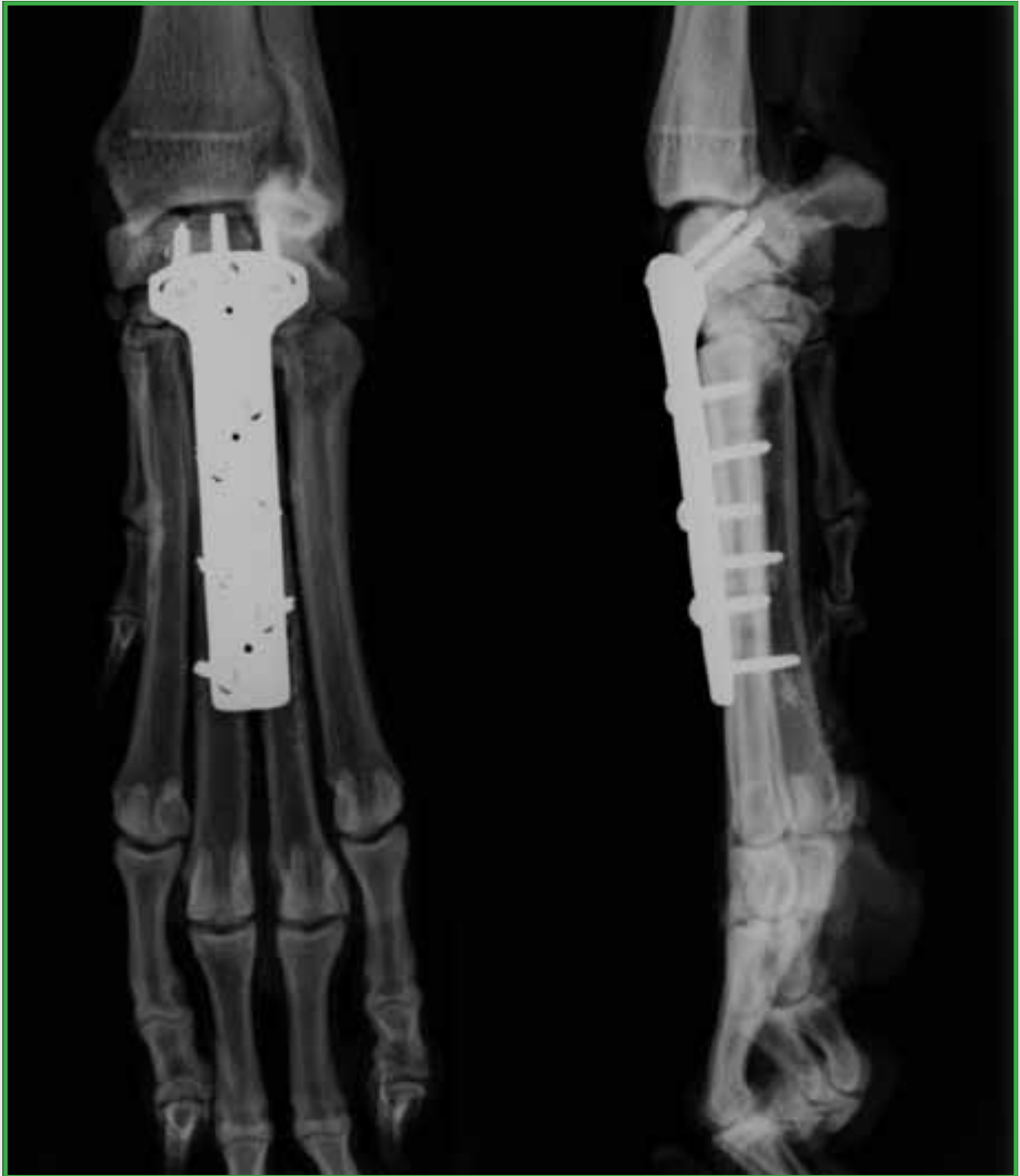

15 The previously sectioned 3rd metacarpal insertion of the extensor carpi radialis is tenodesed using PDS II suture in a three loop pulley suture to the insertion of the tendon on the 2nd metacarpal.

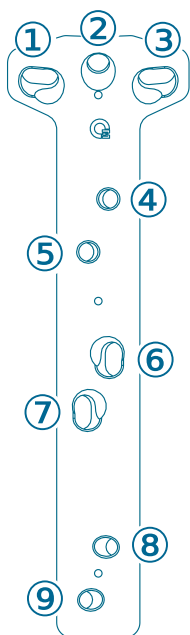
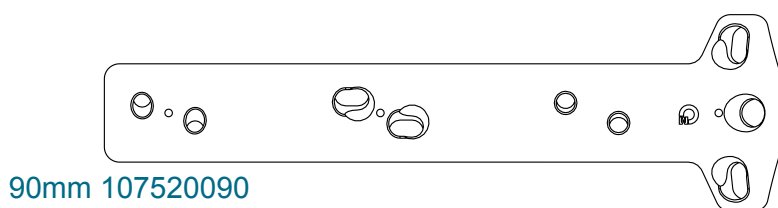
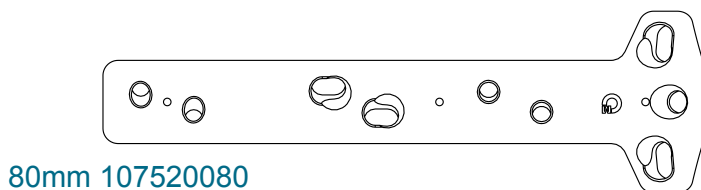
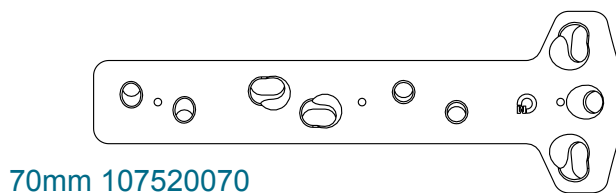
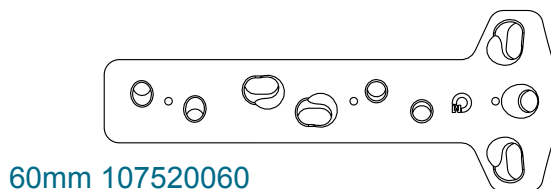
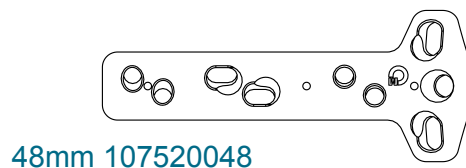
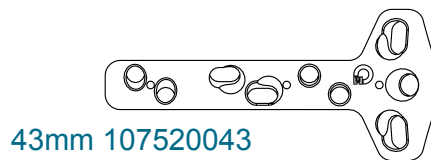
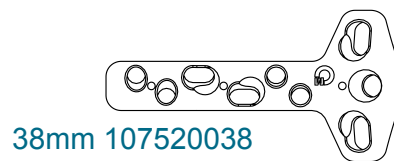


16 The wound is closed routinely and a light dressing used to control wound swelling which can be removed 5 – 7 days after surgery.

ParCA User Guide



ParCA Plates



SUITABLE SCREW SIZES

| | 107520038 | 107520043 | 107520048 | 107520060 | 107520070 | 107520080 | 107520090 |
|---------|---------------------|-----------|-----------|--------------|-----------|--------------|-----------|
| (2) | 2.0 or 2.4 or 2.7mm | | | 2.4 or 2.7mm | | 2.7 or 3.5mm | |
| (1)&(3) | 2.0mm | | | 2.7mm | | 2.7mm | |
| (4)-(9) | 2.0mm | | | 2.7mm | | 2.7mm | |

Orthomed (UK) Ltd

23 Mountjoy Road
Edgerton
Huddersfield
W Yorkshire HD1 5QB

Tel: +44 (0) 845 045 0259

Fax: +44 (0) 845 603 2456

Email: info@orthomed.co.uk

Orthomed Australasia Pty Ltd

15 Waxberry Close
Halls Head, WA, 6210,
Australia

Tel: +61 (0) 8 9590 8850

Fax: +61 (0) 8 9510 9001

Email: info@orthomed.com.au

Orthomed North America Inc.

927 Azalea Lane
Suite A
Vero Beach
Florida 32963

Tel: +1 772-492-0111

Fax: +1 772-492-0444

Email: mike@orthomed.co.uk

Orthomed Technology GmbH

Am Schaafredder 17
24568 Kaltenkirchen
Germany

Tel: +49 (0) 4191 8030013

Fax: +49 (0) 4191 8030014

Email: info@orthomedeu.com

Orthomed (SA) Pty Ltd

Plot 90 Henry St
Shere A.H
Pretoria 0042

Tel: +27 (0) 83 227 8181

Fax: +27 (0) 86 649 0686

Email: info@orthomedsa.co.za



**The home of
Veterinary Orthopaedics**

www.orthomed.co.uk
